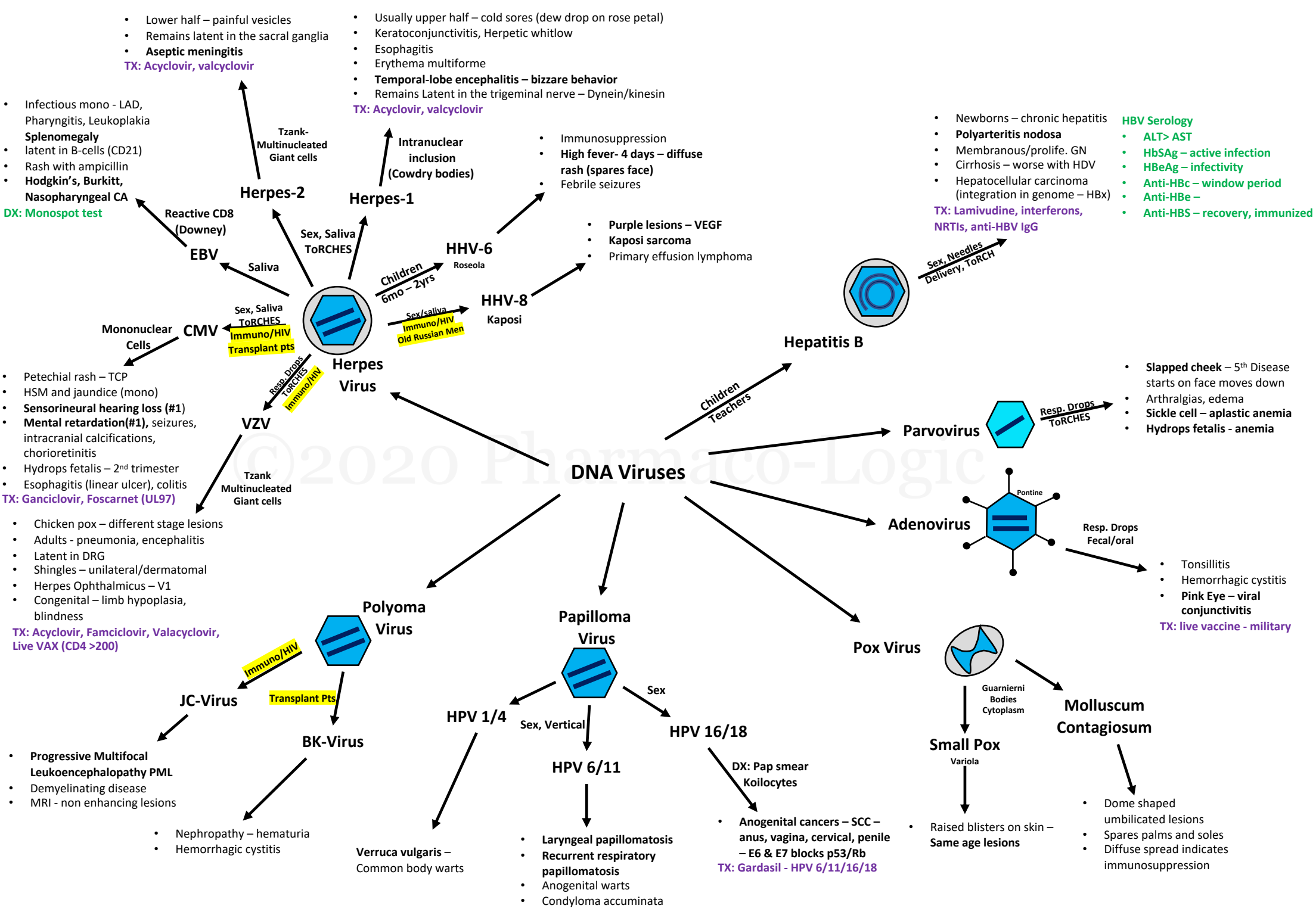
DNA Viruses
Herpes Virus
Herpes-2
Tzank-Multinucleated Giant cells
Lower half – painful vesicles
Remains latent in the sacral ganglia
Aseptic meningitis
TX: Acyclovir, valcyclovir
Herpes-1
Intranuclear inclusion (Cowdry bodies)
Usually upper half – cold sores (dew drop on rose petal)
Keratoconjunctivitis, Herpetic whitlow
Esophagitis
Erythema multiforme
Temporal-lobe encephalitis – bizzare behavior
Remains Latent in the trigeminal nerve – Dynein/kinesin
TX: Acyclovir, valcyclovir
EBV
Saliva
Reactive CD8 (Downey)
Infectious mono - LAD, Pharyngitis, Leukoplakia
Splenomegaly
latent in B-cells (CD21)
Rash with ampicillin
Hodgkin's, Burkitt, Nasopharyngeal CA
DX: Monospot test
Sex, Saliva ToRCHES
HHV-6
Roseola
Children 6mo – 2yrs
Immunosuppression
High fever- 4 days – diffuse rash (spares face)
Febrile seizures
HHV-8
Kaposi
Sex/saliva
Immuno/HIV
Old Russian Men
Purple lesions – VEGF
Kaposi sarcoma
Primary effusion lymphoma
CMV
Mononuclear Cells
Sex, Saliva ToRCHES
Immuno/HIV
Transplant pts
Petechial rash – TCP
HSM and jaundice (mono)
Sensorineural hearing loss (#1)
Mental retardation(#1), seizures, intracranial calcifications, chorioretinitis
Hydrops fetalis – 2nd trimester
Esophagitis (linear ulcer), colitis
TX: Ganciclovir, Foscarnet (UL97)
VZV
Resp. Drops ToRCHES
Immuno/HIV
Tzank Multinucleated Giant cells
Chicken pox – different stage lesions
Adults - pneumonia, encephalitis
Latent in DRG
Shingles – unilateral/dermatomal
Herpes Ophthalmicus – V1
Congenital – limb hypoplasia, blindness
TX: Acyclovir, Famciclovir, Valacyclovir, Live VAX (CD4 >200)
Hepatitis B
Sex, Needles Delivery, ToRCH
Newborns – chronic hepatitis
Polyarteritis nodosa
Membranous/prolife. GN
Cirrhosis – worse with HDV
Hepatocellular carcinoma (integration in genome – HBx)
TX: Lamivudine, interferons, NRTIs, anti-HBV IgG
HBV Serology
ALT> AST
HbSAg – active infection
HBeAg – infectivity
Anti-HBc – window period
Anti-HBe –
Anti-HBS – recovery, immunized
Children Teachers
Parvovirus
Resp. Drops ToRCHES
Slapped cheek – 5th Disease starts on face moves down
Arthralgias, edema
Sickle cell – aplastic anemia
Hydrops fetalis - anemia
Adenovirus
Pontine
Resp. Drops Fecal/oral
Tonsillitis
Hemorrhagic cystitis
Pink Eye – viral conjunctivitis
TX: live vaccine - military
Pox Virus
Guarnierni Bodies Cytoplasm
Small Pox
Variola
Raised blisters on skin – Same age lesions
Molluscum Contagiosum
Dome shaped umbilicated lesions
Spares palms and soles
Diffuse spread indicates immunosuppression
Papilloma Virus
HPV 1/4
Verruca vulgaris – Common body warts
Sex, Vertical
HPV 6/11
Laryngeal papillomatosis
Recurrent respiratory papillomatosis
Anogenital warts
Condyloma accuminata
Sex
HPV 16/18
DX: Pap smear Koilocytes
Anogenital cancers – SCC – anus, vagina, cervical, penile – E6 & E7 blocks p53/Rb
TX: Gardasil - HPV 6/11/16/18
Polyoma Virus
Immuno/HIV
JC-Virus
Progressive Multifocal Leukoencephalopathy PML
Demyelinating disease
MRI - non enhancing lesions
Transplant Pts
BK-Virus
Nephropathy – hematuria
Hemorrhagic cystitis
©2020 Pharmaco-Logic