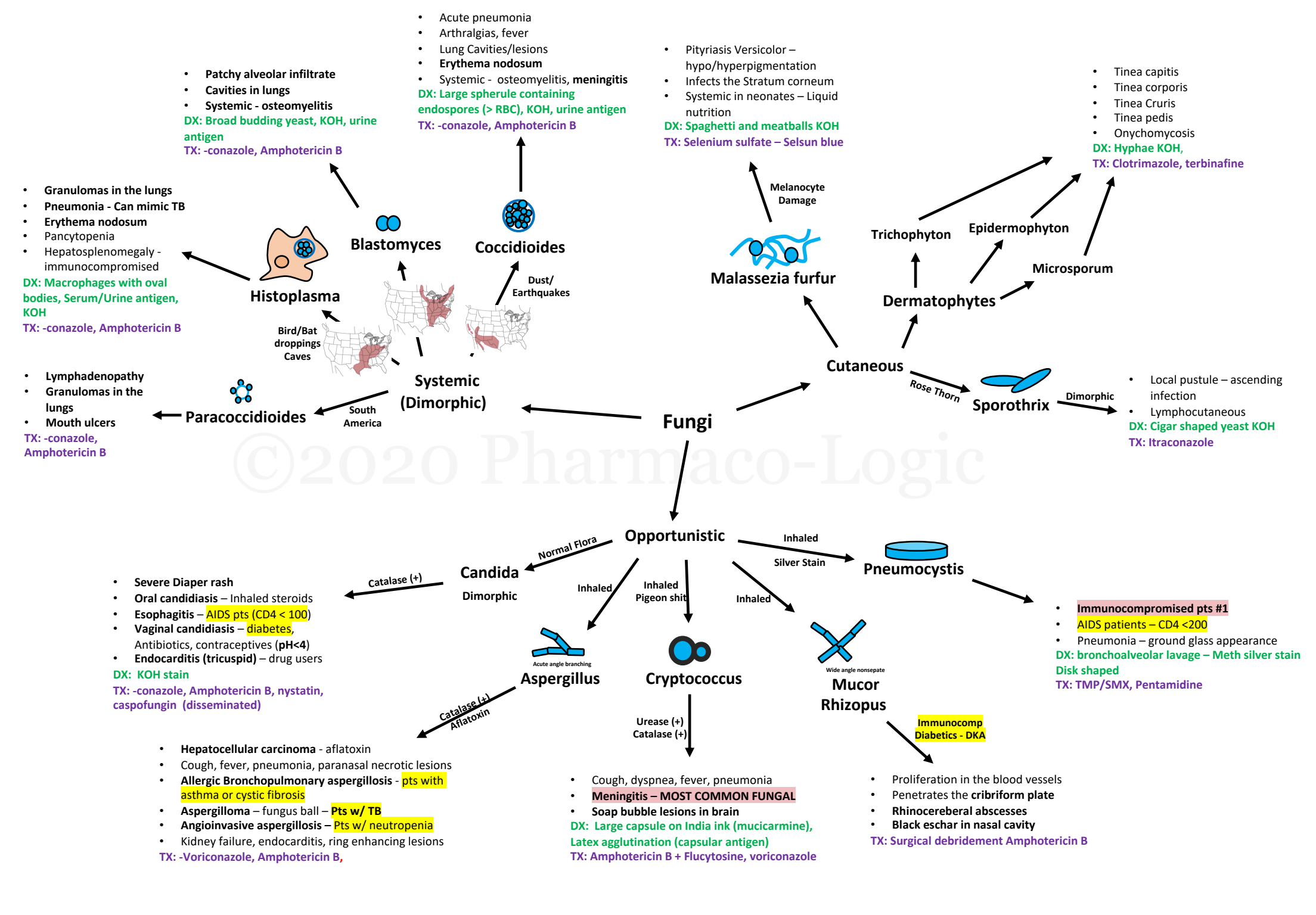
Fungi
Systemic (Dimorphic)
Blastomyces
Patchy alveolar infiltrate
Cavities in lungs
Systemic - osteomyelitis
DX: Broad budding yeast, KOH, urine antigen
TX: -conazole, Amphotericin B
Coccidioides
Acute pneumonia
Arthralgias, fever
Lung Cavities/lesions
Erythema nodosum
Systemic - osteomyelitis, meningitis
DX: Large spherule containing endospores (> RBC), KOH, urine antigen
TX: -conazole, Amphotericin B
Dust/ Earthquakes
Histoplasma
Granulomas in the lungs
Pneumonia - Can mimic TB
Erythema nodosum
Pancytopenia
Hepatosplenomegaly - immunocompromised
DX: Macrophages with oval bodies, Serum/Urine antigen, KOH
TX: -conazole, Amphotericin B
Bird/Bat droppings Caves
Paracoccidioides
Lymphadenopathy
Granulomas in the lungs
Mouth ulcers
TX: -conazole, Amphotericin B
South America
Cutaneous
Malassezia furfur
Melanocyte Damage
Pityriasis Versicolor – hypo/hyperpigmentation
Infects the Stratum corneum
Systemic in neonates – Liquid nutrition
DX: Spaghetti and meatballs KOH
TX: Selenium sulfate – Selsun blue
Dermatophytes
Trichophyton
Epidermophyton
Microsporum
Tinea capitis
Tinea corporis
Tinea Cruris
Tinea pedis
Onychomycosis
DX: Hyphae KOH,
TX: Clotrimazole, terbinafine
Sporothrix
Rose Thorn
Dimorphic
Local pustule – ascending infection
Lymphocutaneous
DX: Cigar shaped yeast KOH
TX: Itraconazole
Opportunistic
Candida
Normal Flora
Dimorphic
Catalase (+)
Severe Diaper rash
Oral candidiasis – Inhaled steroids
Esophagitis – AIDS pts (CD4 < 100)
Vaginal candidiasis – diabetes, Antibiotics, contraceptives (pH<4)
Endocarditis (tricuspid) – drug users
DX: KOH stain
TX: -conazole, Amphotericin B, nystatin, caspofungin (disseminated)
Aspergillus
Acute angle branching
Inhaled
Catalase (+) Aflatoxin
Hepatocellular carcinoma - aflatoxin
Cough, fever, pneumonia, paranasal necrotic lesions
Allergic Bronchopulmonary aspergillosis - pts with asthma or cystic fibrosis
Aspergilloma – fungus ball – Pts w/ TB
Angioinvasive aspergillosis – Pts w/ neutropenia
Kidney failure, endocarditis, ring enhancing lesions
TX: -Voriconazole, Amphotericin B,
Cryptococcus
Inhaled Pigeon shit
Urease (+) Catalase (+)
Cough, dyspnea, fever, pneumonia
Meningitis – MOST COMMON FUNGAL
Soap bubble lesions in brain
DX: Large capsule on India ink (mucicarmine), Latex agglutination (capsular antigen)
TX: Amphotericin B + Flucytosine, voriconazole
Mucor Rhizopus
Wide angle nonsepate
Inhaled
Immunocomp Diabetics - DKA
Proliferation in the blood vessels
Penetrates the cribriform plate
Rhinocereberal abscesses
Black eschar in nasal cavity
TX: Surgical debridement Amphotericin B
Pneumocystis
Inhaled
Silver Stain
Immunocompromised pts #1
AIDS patients – CD4 <200
Pneumonia – ground glass appearance
DX: bronchoalveolar lavage – Meth silver stain
Disk shaped
TX: TMP/SMX, Pentamidine
©2020 Pharmaco-Logic